

# Correlation between morphometry of the uterine artery and estradiol levels in non pregnant domestic pigs (*Sus scrofa domestica*)

Obimbo MM<sup>1,2</sup>, Omwandho C<sup>3</sup>, Ogeng'o JA<sup>1</sup>

<sup>1</sup>Department of Human Anatomy, University of Nairobi, Kenya

<sup>2</sup>Department of Obstetrics and Gynaecology, University of Nairobi, Kenya

<sup>3</sup>Department of Biochemistry, University of Nairobi, Kenya

**Correspondence to:** Dr MM Obimbo, P.O. Box 30197- 00100, Nairobi, Kenya

Email: moses.obimbo@uonbi.ac.ke

## Abstract

**Background:** Structure and morphometry of the uterine artery are important in influencing the pattern of blood flow to the uterus and may be affected by the levels of estradiol. Consequently these may have an effect on reproductive performance.

**Objective:** This study aimed at describing the relation between morphometry of uterine artery from domestic pigs and 17 Beta estradiol.

**Design:** Descriptive cross sectional study.

**Methods:** Blood samples and specimens of uterine artery were obtained from twelve healthy female domestic pigs (*Sus scrofa domestica*). They were fixed in 10% formaldehyde solution, and routinely processed for paraffin embedding. Seven micron thick sections were stained with Mason's Trichrome. Morphometric parameters were measured using Scion image analyzer and estradiol levels assayed by enzyme linked immunoassay technique.

**Results:** The thickness of uterine artery and its luminal diameter increased with advancing age. The level of 17 Beta - Estradiol also steadily rose with age and plateaued by 17th week of domestic pigs' life. Estradiol had a positive effect on growth and development of the uterine artery wall components. Notably, it had a significant growth effect on the tunica media and the overall thickness of the uterine artery and had an apparent luminal narrowing effect.

**Conclusion:** The present study reveals that estrogen may be considered as an important hormone in preservation of uterine arterial wall integrity. It is associated with changes in the uterine artery dimensions important in preparation for increased volume of blood flowing to the uterus prior to the reproductive act.

**Key words:** Uterine artery, Non pregnant, Pig, Morphometry, Estradiol

## Introduction

Estrogen is an important hormone in vascular growth and reproduction (1, 2). It is necessary for fetomaternal adaptation for a favorable pregnancy outcome by stimulating modification in vascular structures (3). The structure and function of uterine artery seem to be affected by changes in serum estrogen (4). At physiological levels, estrogen affects vascular resistance of uterine arteries by directly influencing its structure (5, 6).

There is scanty data relating the levels of estrogen with the morphometry of the uterine artery. Several of these features may be disturbed in impaired vascular hemodynamics such as uterine artery maladaptations in conditions like pre-eclampsia and vasculopathies like acute atherosclerosis. Studying the uterine artery histomorphometric, estradiol levels and their correlations may help illuminate poorly understood aspects of domestic pig, and by inference, human uterine vascular adaptation in non pregnant state. Domestic pigs (*Sus scrofa domestica*), have widely been considered as suitable models in human translational research, surgical models, and procedural training because of their close biological similarities with humans. They have cardiovascular and hemodynamic anatomy and physiology similar to that of humans (7).

Further, their reproductive biology is close to that of humans, for example, the pig has diffuse epitheliochorial placentation with transplacental transport characteristics similar to those of humans (8). Moreover, because the domestic pigs reach reproductive maturity by the age of 4–6 months which is earlier compared to other animals that may be used in such studies, pigs do not have to be housed for as long a time as primates when follow up for changes related to sexual development and changes are critical. It is also easier to study age matched littermates over time. Given the better anatomic similarities, convenience and cost effectiveness of the domestic pigs, results obtained through their study can be translated to improve understanding of human biology and medicine.

## Materials and methods

**Study design and setting:** This was a descriptive cross sectional study. The study animals were purchased from livestock farmers in Ruiru, Thika and Kabete regions of Central Kenya. The specimen preparation, staining and analysis was done in the Department of Human Anatomy, University of Nairobi and The Lancet Laboratories Nairobi.

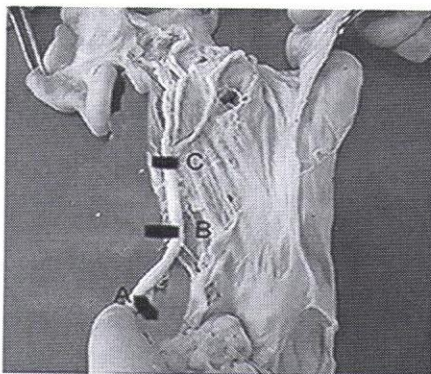
**Study population and sample size:** Twelve female domestic pigs (*Sus scrofa domestica*) aged 5 – 30 weeks were used in this study. All animals were nulliparous. Only those animals certified by a veterinary doctor to be healthy were included in this study.

**Data collection, variables and management:** The animals were euthanized with injections of sodium pentobarbitone 20 mg/ml intravenously and then bled from the marginal ear veins using a 22 gauge needle into a collecting bottle. Midline thoracic and abdominal incisions were made to access the pericardium, abdomen and the pelvic cavity. A canula was inserted into the left ventricle and normal saline introduced draining it out through a slit in the right atrium. Fixation was then done by use of 10% formaldehyde by gravimetric perfusion.

After complete perfusion, the abdominal and pelvic cavities were dissected to expose common iliac, internal iliac and uterine arteries. Five millimeter sections of the uterine artery were harvested in three regions (Figure 1); Main trunk (A - immediately after it is given off the internal iliac), Broad ligament (B - as it enters the broad ligament) and terminal (C - just before anastomosis with ovarian artery). The sections were routinely processed for paraffin embedding. Seven micron thick sections were stained with Mason's Trichrome. Sections were mounted on DPX, examined with Leica BM light microscope of X40. Representative micrographs were taken using orthmax- Zeiss® camera on orthulux® light microscope and analyzed using Scion Image Multiscan software by capturing the sizes of the intima, media and luminal diameter. The software automatically gives the dimensions once the starting and the end points of the measurements in question have been identified. Slides with incomplete wall or torn sections were excluded.

An enzyme linked immunosorbent assay (ELISA) was used to measure 17β-estradiol in the plasma according to the manufacturers' specifications (KA0234, Abnova Corporation, Taiwan). The sensitivity of the assay was 10pg/mL. All samples were run in duplicate. Standards were then graphed and fit using a 4-parameter logistic curve fit. Correlations between the histomorphometrics and estradiol levels were done using mul.

**Figure 1:** Segments of uterine artery from domestic pig



**Ethics:** All procedures were performed according to the *Guide for Care and Use of Laboratory Animals* (NIH publication No. 85-23, revised 1985). The animals were kept at least two together in stables with straw-saw dust ground and free access to an out-door pen during da time. They were fed wetted, granulated full-fodder twice a day with other standard omnivorous diet and had free access to water. The stables were kept at 24°C and a light-dark cycle of 12/12 hours.

**Results**

The uterine artery wall comprised three tunics namely tunica intima, media and adventitia. The morphometric parameters captured were as follows:

a) **Diameter:** The mean luminal diameter of uterine artery in reproductive age was 1186 µm. It varied with age such that by the age of 5 weeks, the mean diameter was 760 µm and increased to mean diameter of 1750 µm at the age of 30 weeks.

b) **The Intimal thickness:** The mean tunica intima thickness was 202 µm. Thickness increased with advancing age. The sharpest increase was after the age of 16 weeks. The mean thickness did not go above 500 µm.

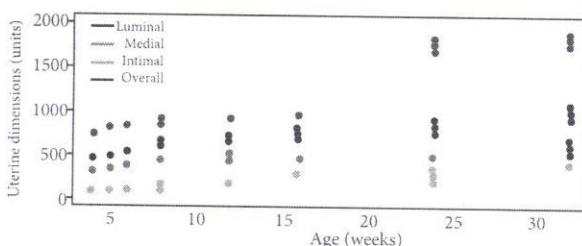
c) **The medial thickness:** The mean medial thickness was 363 µm. There was steady increase in the dimensions of tunica media with age. After the age of sixteen weeks, there seemed to be no significant increase in medial thickness with advancing age. There was an overall increase in wall thickness with advancing age. The wall thickness luminal ratio remained constant with age. Increase in luminal diameter was coupled with proportionate increase in wall thickness (Table 1).

**Table 1:** Changes in wall thickness luminal ratio with age

Age range (weeks)	Mean luminal diameter, µm	Mean overall wall thickness, µm	Wall thickness/luminal diameter	Wall thickness luminal ratio
5 - 10	760	451	0.59	1:2
11- 15	876	493	0.54	1:2
16 - 20	1128	538	0.47	1:2
21- 25	1490	731	0.48	1:2
26 - 30	1786	903	0.50	1:2

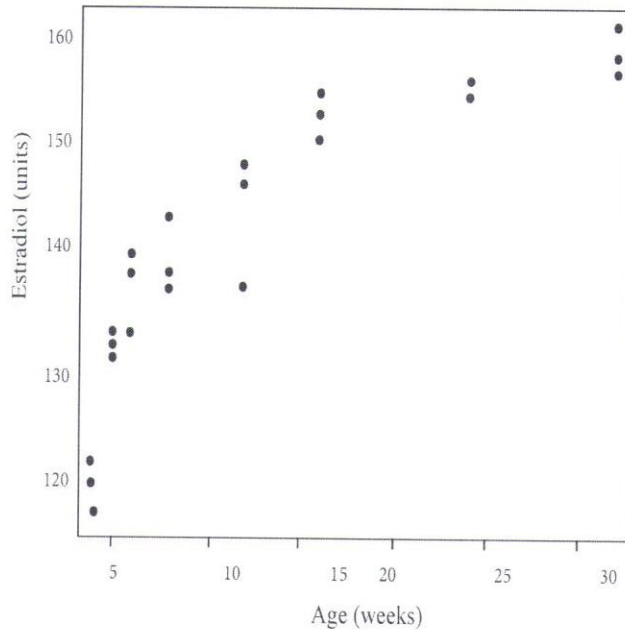
Figure 1 provides a summary of changes in the uterine histomorphometrics with advancing age. As shown in the figure, most marked was increase in the luminal diameter with age.

**Figure 1:** Changes in uterine histomorphometry with age



**Estradiol levels:** Thirty three animals were included in this assay. The average estradiol (E2) profiles for the non-pregnant females varied from 38 to 159pg/ml and did differ although not significantly between age groups. The levels of estradiol steadily rose with age up to the 17<sup>th</sup> week of life (Figure 2). At the end of the 17<sup>th</sup> week, there was a short elevation, followed by a continuous but slow increase throughout the period examined to the 30<sup>th</sup> week.

**Figure 2:** Changes of estrogen with animal growth in non pregnant domestic pig



**Effect of estradiol on uterine artery of non pregnant domestic pig:** Estradiol had a positive growth and development effect on the uterine artery wall components. Notably, it had a significant growth effect on the tunica media and the overall thickness of the uterine artery and had an apparent luminal narrowing effect.

When multivariate analysis was performed to find the effect of estradiol on growth of media, it was found that medial thickness increased by 65.8µm per week independent of the estradiol concentration this being statistically significant <0.001. It was also found that medial thickness increased by 4.27µm per unit increase in estradiol concentration <0.001. This change was also statistically significant. The total overall thickness examined against time and rising estradiol levels showed that increase in the overall thickness of the uterine artery was dependant on both time and estradiol levels (Table 2).

**Table 2:** Multivariate analysis of overall thickness and estradiol

	Coefficient	P value
Week	83.6	0.003
Estradiol	5.31	<0.001
week * estradiol	-0.43	0.009

Overall thickness increases by 83.6µm per week independent of the estradiol concentration and 5.31µm dependent on estradiol levels. These observations were statistically significant.

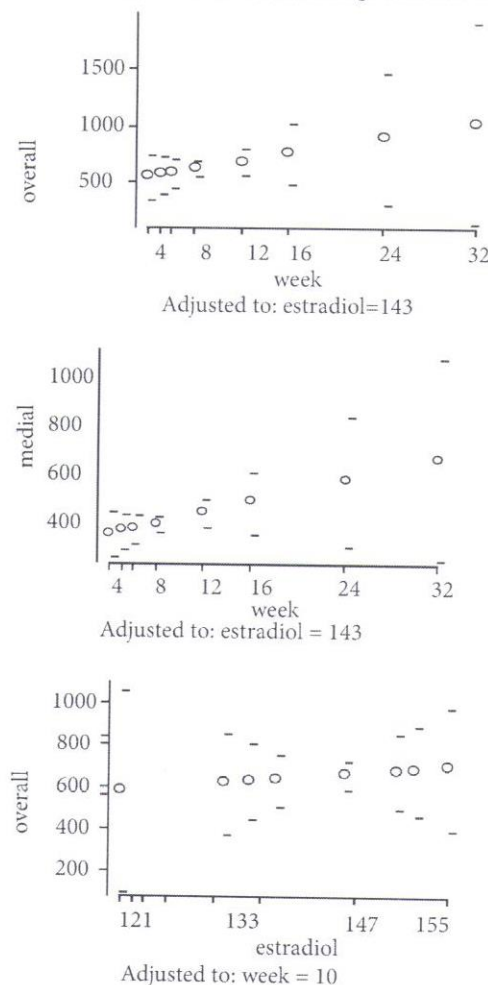
The rate of luminal diameter increase was at 9.1µm per week. A unit increase in estradiol concentration led to a narrowing of the lumen by 6.9 µm. Although there is a net increase in the luminal diameter with time (age in weeks), higher estradiol concentrations tended to reduce the luminal diameter (Table 3). This was, however, not statistically significant.

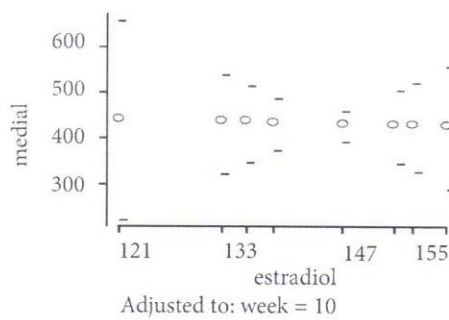
**Table 3:** Multivariate analysis of luminal diameter and estradiol

	Coefficient	P-value
Week	9.1	0.933
Estradiol	-6.9	0.123
week * estradiol	0.24	0.724

In general, estradiol had a somatotropic effect on uterine artery. Figure 3 summarizes the changes that take place in the dimensions of the uterine artery with time and with changes in estradiol levels.

**Figure 3:** Summary of changes in the dimensions of the uterine artery with time and rising estradiol levels





## Discussion

The luminal diameter, intimal and medial thickness increased with age. The increase in luminal diameter is a response to increased vascular demand that occurs with age (9, 10). A possible failure to increase the luminal diameter as an animal grows and reaches reproductive maturity could lead to infertility as a result of decreased blood flow (11). It is apparent that the uterine artery attains its maximal luminal diameter at 30 weeks when it has achieved its full sexual and reproductive maturity. Seemingly, therefore the growth in the vessel lumen prepares the uterine artery for reproduction.

The mean tunica intima thickness was 202  $\mu\text{m}$ . Thickness increased with advancing age. Increase in the thickness of intima in vascular beds with advancing age has been reported (12, 13). There was steady increase in the dimensions of tunica media with age. After the age of sixteen weeks, there seemed to be no significant increase in medial thickness with advancing age. The structural basis for the increase in the medial thickness with age in this study may be explained in terms of vascular smooth muscle cell hypertrophy, increase in number of circular smooth muscle layers, the development of the longitudinal muscle band and increased uterine artery blood flow. In the large muscular arteries, at an early age, increase in medial mass is normally due to increase in the number of the smooth muscle cell layers and later due to further hypertrophy of the smooth muscle cells (14).

There was overall increase in wall thickness with advancing age but the wall thickness: luminal ratio remained constant with age as a result of concomitant increase in the luminal diameter. This finding is at variance with the observation in the mesenteric vasculature from mature rats (15, 16). In the current study, wall thickness: luminal ratio remained constant reflecting eutrophic remodelling (17). Such a remodelling process has been evidenced in isolated arterioles and small arteries that have minimally been exposed to increased wall pressure.

The average E2 profiles for the non-pregnant females varied from 38 to 159pg/ml. The levels appeared to plateau by 16<sup>th</sup> week of pigs' life. These results indicate that plasma estradiol levels correlate well with the stage of sexual development. During early development in females, the hypothalamic-pituitary-gonadal axis is active during the first months of postnatal life, allowing for rapid adaptation to the environment but is thereafter

believed to be relatively quiescent until it is reactivated when an animal enters puberty at 24 weeks (18, 19). Young animals are highly sensitive to estradiol because of increased expression of estrogen and androgen receptors in sex steroid sensitive tissues.

Sex-steroid hormones have been shown to modulate vascular function in adult humans and experimental animals (20, 21). Estrogen has direct effects on the endothelium, smooth muscle, and interaction of platelets with the vascular wall (22, 23) through regulation of production of vasoactive factors from endothelial cells such as nitric oxide (NO), C-type natriuretic peptide (CNP), endothelin prostacyclin, angiotensin converting enzyme, vascular adhesion molecules, and chemoattractants. The findings in the current study show that plateau of estrogen hormone level is attained when the pig is in transiting from the juvenile to mature state which occurs at five months (24). Developmental transition to sexual maturity in female pigs is therefore characterized by constant concentration of estrogen hormone levels with small variations which may be explained by differences in times related to ovulation. Variation in hormonal assay in non pregnant state when the pig attains maturity can be influenced by external factors such as exposure to male pigs (24) since pigs used in this study were housed in a common facility within sight, sound, and smell of male animals.

Estradiol levels had effect on various uterine artery morphometrics. On tunica media when multivariate analysis was performed to find the effect of estradiol on growth of media, it was found that medial thickness increased significantly per week independent of the estrogen concentration and also significantly dependent on estrogen concentration ( $p < 0.001$ ,  $p < 0.001$  respectively). This finding indicates that growth and integrity of tunica media is both estrogen and time dependent. Estrogen preserves a thin intima thickness and either grows or maintains media thickness and intima/media ratio.

Estrogen in this regard may be considered as an important hormone in preservation of uterine arterial wall integrity. The general loss of muscle and connective tissue elements that normally occurs with advancing age may be ameliorated by estrogen therapy (25, 26) and this might help to explain the observed thickening of the artery media layer with growth in reproductive period and probably decline in thickness with normal aging. It is however, generally thought that muscular arteries such as the uterine artery have a lesser response to estrogen compared to elastic arteries (27). Clinically, this study has advanced that estradiol maintains a thin tunica intima and the integrity of media for proper vascular function, supporting evidence of the role played by estradiol in other vascular trees (28, 29). Should the levels of estradiol fall, for example due to menopause or bilateral oophorectomy, chances are that uterine vascular biology is affected either by developing a thick intima and or weakening of

the tunica media. Early loss of endogenous estradiol in women due to any cause may abrogate age-related uterine vascular remodeling and therefore consideration of supplementation with exogenous estrogens may be necessary to maintain the integrity of the uterine vascular system for proper reproductive functions.

### Conclusion

The present study reveals that estrogen may be considered as an important hormone in preservation of uterine arterial wall integrity. It is associated with changes in the uterine artery dimensions important in preparation for increased volume of blood flowing to the uterus prior to the reproductive act.

### Acknowledgement

We would like to thank the National Council for Science and Technology and University of Nairobi Deans Committee for their financial support. Dr. Dedan Opondo for his input in different parts of this study.

### References

- Marin, G., Domené, H.M., Barnes, K.M., Blackwell, B.J., Cassorla F.G and Cutler G.B. Jr. The effects of estrogen priming and puberty on the growth hormone response to standardized treadmill exercise and arginine-insulin in normal girls and boys. *J Clin Endocrinol Metab.* 1994; **79**:537–541.
- Leung, K.C., Johannsson, G., Leong, G.M. and Ho, K.K. Estrogen regulation of growth hormone action. *Endocr Rev.* 2004; **25**:693–721.
- Hall, J.M., Couse, J.F. and Korach, K.S. The multifaceted mechanisms of estradiol and estrogen receptor signaling. *J Biol Chem.* 2001; **276**:36869–36872.
- Bell, C. and Vogt, M. Release of endogenous noradrenaline from an isolated muscular artery. *J Physiol.* 1971; **215**: 509-520.
- Furchgott, R.F. and Zawadzki, J.V. The obligatory role of endothelial cells in the relaxation of arterial smooth muscle by acetylcholine. *Nature.* 1980; **288**:373-376.
- Vane, J.R. Anggard, E.E. and Botting, R. Regulatory functions of the vascular endothelium. *N Engl J Med.* 1990; **323**:27–36.
- Swindle, M.M. Swine in the Laboratory: Surgery, Anesthesia, Imaging and Experimental Techniques. 2nd ed. Boca Raton, FL: CRC Press; 2007.
- Swindle, M.M. and Smith, A.C. Comparative anatomy and physiology of the pig. *Scand J Lab Anim Sci.* 1998;**25**(suppl 1):1–10.
- Ferrara, N., Chen, H., David-Smith, T., Gerber, H.P., et al. Vascular endothelial growth factor is essential for corpus luteum angiogenesis. *Nat Med.* 1998; **4**:336–340.
- Bluth, E. I., Benson, B and Arger, P.H. Ultrasound in Obstetrics and Gynecology: a practical approach. 2009; <http://books.google.co.za/books?id> Accessed on September, 13<sup>th</sup> 2013.
- Goswamy, R.K., Williams, G. and Steptoe, P.C. Decreased uterine perfusion – a cause of infertility. *Human Rep.* 1988; **3**:955- 959.
- Habermehl, D.A., Janowiak, M.A., Vagnoni, K.E., Bird, I.M. and Magness, R.R. Endothelial vasodilator production by uterine and systemic arteries. IV. Cyclooxygenase isoform expression during the ovarian cycle and pregnancy in sheep. *Biol Reprod.* 2000; **62**:781–788.
- Laurent, S., Cockcroft, J., Van Bortel, L., et al. Expert consensus document on arterial stiffness: methodological issues and clinical applications. *Eur Heart J.* 2006;**27**:2588–2605.
- Lee, S. and Schmid-Schonbein, G.W. Biomechanical model for the myogenic response in the microcirculation. II. Experimental evaluation in rat cremaster muscle. *J Biomech Eng.* 1996; **118**: 152–157.
- Meininger, G.A. and Davis, M.J. Cellular mechanisms involved in the vascular myogenic response. *Am J Physiol Heart Circ Physiol.* 1992;**263**: H647–H659.
- Jackson, P.A. and Duling, B.R. Myogenic response and wall mechanics of arterioles. *Am J Physiol.* 1989; **257**: H1147-H1155.
- Intengan, H.D. and Schiffrin, E.L. Vascular remodeling in hypertension: roles of apoptosis, inflammation, and fibrosis. *Hypertension.* 2001; **38**:581–587.
- Andersson, A.M. and Skakkebaek, N.E. Exposure to exogenous estrogens in food: possible impact on human development and health. *Eur J Endocrinol.* **1999**;**140**:477-485.
- Chellakooty, M., Schmidt, IM., Haavisto, A.M., Boisen, K.A., Damgaard, I.N. et al. Inhibin A, inhibin B, follicle-stimulating hormone, luteinizing hormone, estradiol, and sex hormone-binding globulin levels in 473 healthy infant girls. *J Clin Endocrinol Metab.* 2003; **88**:3515-3520.
- Caulin-Glaser, T., Garcia-Cardena, G., Sarrel, P., Sessa, W.C. and Bender, JR. 17β-Estradiol regulation of human endothelial cell basal nitric oxide release, independent of cytosolic Ca<sup>2+</sup> mobilization. *Circ Res.* 1997;**81**: 885-892.
- Bracamonte, M.P., Jayachandran, M., Rud, K.S. and Miller, V.M. Acute effects of 17β-estradiol on femoral veins from adult, gonadally intact and ovariectomized female pigs. *Am J Physiol Heart Circ Physiol.* 2002; **283**: H2389-H2396.
- Harder, D.R. and Coulson, P.B. Estrogen receptors and effects of estrogen on membrane electrical properties of coronary vascular smooth muscle. *J Cell Physio.* 1979;**100**: 375-382.
- Jayachandran, M. and Miller, V.M. Hormones and Heart Disease. Philadelphia, PA. *Harcourt Health Sci.* 2002; 207-230.

24. Esbenshade, K.L., Paterson, A.M., Cantley, T.C. and Day, B.N. Changes in plasma hormone concentrations associated with the onset of puberty in the gilt. *J Anim Sci.* 1982;**54**: 320-324.
25. D'Angelo, G. and Osol, G. Modulation of uterine resistance artery lumen diameter by calcium and G protein activation during pregnancy. *Am J Physiol.* 1994;**267**: H952-H961.
26. Punnonen, R., Jokela, H., Heinonen, P.K., Aine, R. and Dastidar, P. Hormone replacement therapy and atherosclerosis. *J Reprod Med.* 1995;**40**:267-272.
27. Fischer, G.M. and Swain, M.L. Effect of sex hormones on blood pressure and vascular connective tissue in castrated and non-castrated male rats. *Am. J. Physiol.* 1977; **237**:617.
28. Grady, D., Rubin, S.M., Petitti, D.B., Fox, C.S., Black, D., Ettinger, B., *et al.* Hormone therapy to prevent disease and prolong life in postmenopausal women. *Ann Intern Med.* 1992; **117**:1016-1037.
29. Viscoli, C.M., Brass, L.M., Kernan, W.N., Sarrel, P.M., Suissa, S., *et al.* A clinical trial of estrogen-replacement therapy after ischemic stroke. *N Engl J Med.* 2001; **345**:1243-1249.